



Crossed Fused Renal Ectopia

P Demelo-Rodríguez*, E Cervilla Muñoz and F Galeano Valle

Department of Orthopaedics, Hospital General Universitario Gregorio Marañón, Spain

Introduction

Crossed renal ectopia is a rare developmental abnormality of the urinary tract, which is usually described as incidental finding, and whose incidence is approximately 1 per 75,000 autopsies.

Case Presentation

An 83 year-old male without urological history was admitted to our center due to constitutional symptoms and uncontrollable vomiting. The imaging and pathology confirmed the diagnosis of biliary carcinoma. In the abdominal computed tomography (CT) both kidneys were fused and located to the right of the midline, an image compatible with crossed fused renal ectopia (Figure 1). Both ureters were preserved.

Discussion

Crossed renal ectopia (which can be fused -90% of cases- or unfused) occurs when the ectopic kidney is located on opposite side opposite to its insertion in the bladder. It is a rare congenital anomaly. Sometimes the blood vessels responsible for irrigation of the ectopic kidney cross the midline and may be responsible for stenosis of the ureteropelvic junction of ectopic kidney or the normally placed kidney. Most cases of crossed renal ectopia are asymptomatic and the diagnosis is made when pathology (such as infections, urolithiasis, tumors or other less common) affects the ectopic kidney. Diagnosis can be performed by ultrasound, intravenous urography or anteropgrade pyelography, isotopic studies, computed tomography and magnetic resonance imaging. This congenital anomaly does not require further treatment if the patient is asymptomatic.

OPEN ACCESS

*Correspondence:

Pablo Demelo Rodríguez, Hospital
General Universitario Gregorio
Marañón, Madrid, Spain,
E-mail: pbdemelo@hotmail.com

Received Date: 26 Sep 2017

Accepted Date: 09 Nov 2017

Published Date: 25 Nov 2017

Citation:

Demelo-Rodríguez P, Cervilla Muñoz E,
Galeano Valle F. Crossed Fused Renal
Ectopia. *Ann Clin Case Rep.* 2017; 2:
1477.

ISSN: 2474-1655

Copyright © 2017 P Demelo-
Rodríguez. This is an open access
article distributed under the Creative
Commons Attribution License, which
permits unrestricted use, distribution,
and reproduction in any medium,
provided the original work is properly
cited.

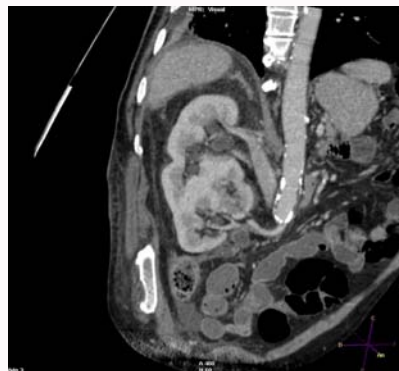


Figure 1: Abdominal CT shows in the absence of kidney in the left abdomen and crossed fused renal ectopia in the right abdomen.