



Cannabinoid Hyperemesis Syndrome

Gabriela Strey*

Department of Internal Medicine, Hervey Bay Hospital, Australia

Introduction

Medical cannabis is used as an antiemetic and appetite stimulant in cancer and HIV patients, but cannabis as the most widely used illicit drug in Australia can have a paradoxical proemetic effect known as cannabinoid hyperemesis syndrome (CHS).

We describe in this case a patient with prior presentations for nausea and vomiting who was admitted with characteristic features of Cannabis hyperemesis syndrome complicated by severe electrolyte disturbances and metabolic alkalosis.

Case Presentation

A 22-year-old Caucasian female presented to our rural hospital with colicky upper abdominal pain, nausea and intractable vomiting. In the last year she had presented a couple of times with similar symptoms. She smoked up to 20 cones a day and lost around 5 kg of weight in the last 3 months. Of note was a history of congenital atrial septum defect with patch repair and a higher degree atrial ventricular block for. She had denied pacemaker implantation.

On physical examination, she was afebrile, blood pressure 116/74 mmHg, pulse 61 beats per minute, body weight: 51.4kg, height 168cm (BMI: 18.2). Her abdomen was soft but exhibited tenderness in the epigastric area with decreased bowel sounds but no rebound tenderness or guarding.

Paraclinic

Laboratory studies demonstrated a pH 7.649, Sodium 109 mmol/l (135 - 145), Potassium 1.9 mmol/l (3.5 - 5.1), Chloride 58 mmol/l (100-110), Osmolality 230 mmol/l (275 - 295). Magnesium 0.61 mmol/l (0.70-1.10) Leucocytes 29.3 x 10⁹/L (4-11). The remainder of the tests were normal.

The urine drug screening was positive for Cannabinoids.

The Electrocardiogram (ECG) showed a first degree atrial-ventricular block (AVB) with multiple polymorphic ventricular extrasystoles and couplets and prolonged QTc (Figure 1).

Clinical course

Over the course of 2 days she received a total of 480 mmol of potassium and 30 mmol Magnesium intravenously. The ECG changes returned to baseline (intermittent second and third degree AVB with idioventricular rhythm). She was discharged home in a stable condition, her leukocyte count had normalised.

OPEN ACCESS

*Correspondence:

Gabriela Strey, Department of Internal Medicine, Hervey Bay Hospital, Nissen Street, Hervey Bay, Queensland, 4655, Australia,

E-mail: gabriela.strey@health.qld.gov.au

Received Date: 18 Aug 2017

Accepted Date: 11 Oct 2017

Published Date: 13 Oct 2017

Citation:

Strey G. Cannaboid Hyperemesis Syndrome. *Ann Clin Case Rep.* 2017; 2: 1446.

ISSN: 2474-1655

Copyright © 2017 Gabriela Strey. This is an open access article distributed under the Creative Commons Attribution License, which permits unrestricted use, distribution, and reproduction in any medium, provided the original work is properly cited.

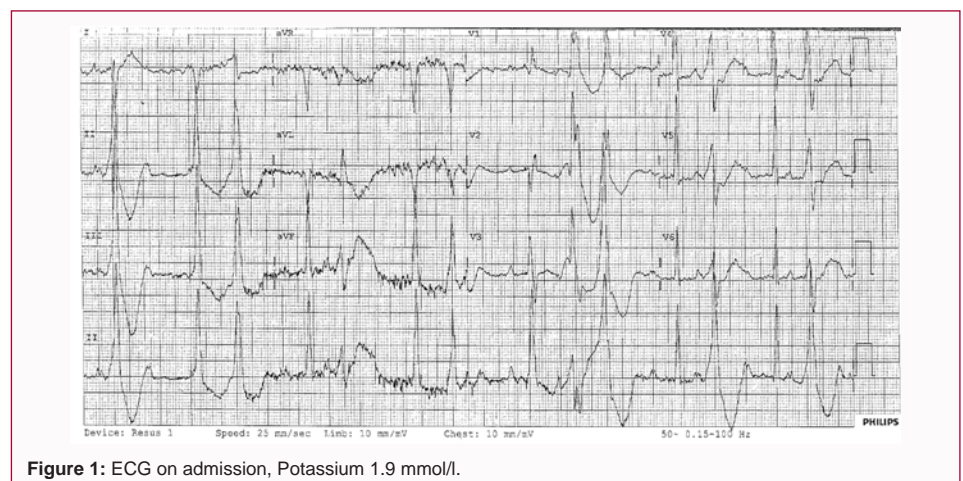


Figure 1: ECG on admission, Potassium 1.9 mmol/l.

Table 1: Proposed diagnostic criteria for CHS [1].

Essential for diagnosis
Long-term cannabis use
Major features
Severe cyclic nausea and vomiting
Resolution with cannabis cessation
Relief of symptoms with hot showers or baths
Abdominal pain, epigastric or periumbilical
Weekly use of marijuana
Supportive features
Age less than 50 years
Weight loss of >5 kilogram
Morning predominance of symptoms
Normal bowel habits
Negative laboratory, radiographic, and endoscopic test results

Discussion

Marijuana is one of the most commonly abused drugs worldwide. Cannabinoid Hyperemesis Syndrome was first described by Allen in Australia in 2004. In 2012, Simonetto et al. proposed diagnostic criteria (Table 1) based on a study involving 98 patients.

The symptoms have been reported to be alleviated temporarily by taking a hot shower or bath or more permanently by abstaining from cannabis use. Our patient spent hours taking hot showers trying to relieve her pain [1].

CHS diagnoses are relatively few in number and no epidemiological data on the incidence or prevalence exist. Therefore it is often unrecognized by clinicians leading to extensive and expensive workup of these patients with cyclical symptoms [1].

CHS should be considered in younger patients with long-term cannabis use and recurrent nausea, vomiting, and abdominal pain. Knowledge and early recognition of this syndrome will reduce the ordering of unnecessary and expensive investigations, as well as inappropriate medical and surgical treatment in patients presenting with recurrent vomiting of unknown cause [2].

References

1. Anene Ukaigwe, Paras Karmacharya, and Anthony Donato. A Gut Gone to Pot: A Case of Cannabinoid Hyperemesis Syndrome due to K2, a Synthetic Cannabinoid. *Case Reports in Emergency Medicine*. 2014. Article ID 167098.
2. Gabriela Strey. Two faces of cannabis. *Aust J Rural Health*. 2016; 24: 340–341.