



A Case Report Describing Intraoperative Movement of Toric Intraocular Lens (IOL) In a Patient with Keratoconus and High Astigmatism

Alanna Wood^{1*}, Erin Thornell² and Smita Agarwal²

¹Department of Ophthalmology, Hornsby Ku-ring-gai Hospital, Australia

²Department of Ophthalmology, Wollongong Eye Specialists, Australia

Abstract

Background: We present a case of intraoperative rotation of a toric lens during cataract surgery in a patient with high irregular astigmatism as a result of keratoconus.

Case Presentation: Despite numerous attempts to stabilise intraoperatively, the intraocular lens (IOL) continued to rotate until a capsular tension ring (CTR) was inserted. Good centration and rotational stability was achieved and remained at follow-up.

Conclusions: We propose the possibility of an irregularly shaped capsular bag in some patients with keratoconus and high astigmatism, potentially causing the IOL to rotate to a position that better accommodates the conformation of the capsular bag. Preoperative assessment of the shape of the capsular bag in patients with keratoconus may be beneficial in preventing intraoperative rotation of IOLs.

Keywords: IOL; Rotational instability; Keratoconus; Astigmatism

Introduction

Corneal ectatic disorders such as keratoconus can result in progressive corneal thinning, irregular corneal astigmatism and visually significant cataract at younger ages compared to the general population [1]. Toric IOL implantation during cataract surgery in those with significant astigmatism can provide satisfactory vision, however accurate centration and stable alignment are paramount to achieving this outcome [2]. Rotation has been reported as one of the most common causes of patient dissatisfaction in the immediate postoperative period particularly with high-powered toric lenses, with incidence of rotation being brand and type specific [2,3]. Previous case studies that have reported toric IOL instability have described utilising both single and double CTR implantation to fixate the lens in the correct position [4,5]. Implantation of IOLs in eyes with forme fruste keratoconus without the incidence of rotational instability has also been reported [6]. However, we report a case of intraoperative rotation of a toric IOL in an eye with keratoconus and high astigmatism that required the insertion of a CTR to stabilise the lens.

Case Presentation

Mrs CB, a 53-year-old caucasian female presented complaining of decreased vision bilaterally which was long-standing in nature, being spectacle-dependent since childhood. Her symptoms included blurring of vision, glare and difficulty reading at short and long distances. On slit lamp examination, Mrs CB was found to have bilateral nuclear and cortical cataracts. No features of pseudo-exfoliation syndrome or capsular fibrosis were identified and she had not had prior ocular surgery performed. Her best corrected visual acuity (BCVA) preoperatively was 6/12 in the right eye and 6/9 in the left eye. Refraction in the right eye was +6.0DS/-5.5DC x 15 degrees and in the left eye +6.25DS/-5.5DC x 150 degrees. Topography demonstrated keratoconus and biometry showed an axial length of 22.14 mm.

Intraoperatively, phacoemulsification was successfully performed bilaterally and Rayner T-flex™ hydrophilic Aspheric 573T 12 mm IOLs were implanted and dialled to the required positions. The right-sided IOL rotated immediately and continued to rotate despite several attempts to reposition in the desired axis. Options for intraoperative lens stabilisation were CTR insertion or

OPEN ACCESS

*Correspondence:

Alanna Wood, Hornsby Ku-ring-gai Hospital, Palmerston Road, Hornsby, NSW 2077, Australia,
E-mail: wood.alanna@gmail.com

Received Date: 05 Jul 2017

Accepted Date: 06 Oct 2017

Published Date: 10 Oct 2017

Citation:

Wood A, Thornell E, Agarwal S. A Case Report Describing Intraoperative Movement of Toric Intraocular Lens (IOL) In a Patient with Keratoconus and High Astigmatism. *Ann Clin Case Rep.* 2017; 2: 1441.

ISSN: 2474-1655

Copyright © 2017 Alanna Wood. This is an open access article distributed under the Creative Commons Attribution License, which permits unrestricted use, distribution, and reproduction in any medium, provided the original work is properly cited.

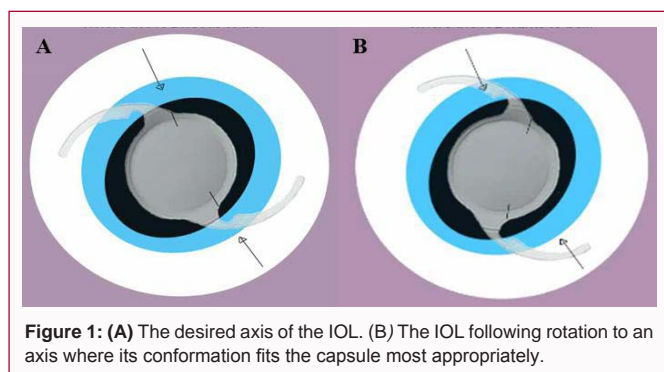


Figure 1: (A) The desired axis of the IOL. (B) The IOL following rotation to an axis where its conformation fits the capsule most appropriately.

replacement of the lens with a non-toric IOL leaving her with residual astigmatism. Intraoperatively, the IOL, despite being well centred, was found to have rotated to 67 degrees from the desired axis of 106 degrees. The lens was repositioned and a CTR was implanted into the bag, achieving immediate rotational stability. No zonular weakness was noted intraoperatively. Postoperative follow-up the next day revealed an IOL that was well centred and aligned at the desired axis, with BCVA in the right eye of 6/7.5. Stability was maintained at 3 and 6 months postoperatively.

Discussion

The correction of irregular astigmatism in eyes with keratoconus remains challenging, and for this reason those undergoing IOL insertion should be carefully assessed preoperatively [6]. Up to a third of the astigmatic correction is lost if the lens rotates by 10 degrees, and astigmatism exceeding preoperative values results if rotation greater than 30 degrees occurs [2,7]. Implant material, haptic design and IOL size in relation to capsular bag are all features that can affect spontaneous rotation and need to be considered prior to selecting an appropriate IOL [2,8]. Over time the capsular bag contracts around the haptics to enclose and secure the lens, but rotation of the lens remains a possibility before this contraction occurs [9]. Therefore, it is important to choose correct IOL size for the bag, as well as create friction between the IOL haptic and the bag to prevent early rotation of the lens. Those made from silicone demonstrate higher postoperative rotation rates and often require surgical realignment [3]. While the lens used was a hydrophilic lens, hydrophobic lenses have generally shown greater rotational stability in the post-operative period perhaps owing to a greater adherence to the capsule [10,11]. In our case, the lens could not be positioned at the desired axis even intraoperatively. Regarding haptic design, both plate haptics and open-loop haptics are options, with plate haptics conferring less postoperative rotation than open-loop [7]. With respect to the IOL size in relation to the capsular bag, there is a risk of rotation if the IOL is too small and a risk of the capsular bag stretching and distorting if too large [8]. To ensure accurate fitting prior to the procedure, the horizontal corneal diameter and axial length are substituted into known formulas to calculate the capsular bag diameter [9].

Despite these parameters being carefully assessed preoperatively, we propose that in some patients with keratoconus and higher astigmatism, the shape of the capsular bag may also confer a degree of instability during and after implantation of a toric lens. In the case presented, the IOL continually rotated intraoperatively, perhaps owing to a capsular bag that was oval in shape with an apex at 65

degrees, causing the lens to rotate to this position rather than the desired 106 degree axis (Figure 1). While there are other features as mentioned that may contribute to rotation of an IOL postoperatively, we propose that in some patients with keratoconus and with high astigmatism, the capsular bag may be irregularly shaped, causing the IOL to rotate to a position that better accommodates the conformation of the capsular bag. Currently, no preoperative analysis takes place to predict the shape of the capsular bag in an eye with keratoconus. Techniques such as optical coherence tomography, B-scan, ultrasound biomicroscopy or magnetic resonance imaging could be employed to determine the shape and orientation in this selected cohort.

Once a lens has rotated intraoperatively, management options include corneal incisions or laser vision correction, as well as trans-scleral suture fixation of the toric IOL. Alternatively, intraoperative insertion of a CTR into the capsular bag enforces symmetry within the bag, stretching the equator and flattening the bag in the anterior and posterior axes, thereby preventing rotation [4]. In this case, a CTR was used to achieve rotational stability in a patient with irregular astigmatism secondary to keratoconus, yielding good visual acuity results that persisted postoperatively. Based on our experience, we are suggesting that preoperative assessment of the capsular bag, possibly through a modality such as B-scan, may be beneficial in planning the surgical outcomes of patients with keratoconus.

References

- Thebpatiphat N, Hammersmith KM, Rapuano CJ, Ayres BD, Cohen EJ. Cataract surgery in keratoconus. *Eye Contact Lens*. 2007; 33: 244-246.
- Chang DF. Early rotational stability of the longer Staar toric intraocular lens: fifty consecutive cases. *J Cataract Refract Surg*. 2003; 29: 935-940.
- Buckhurst PJ, Wolffsohn JS, Naroo SA, Davies LN. Rotational and centration stability of an aspheric intraocular lens with a simulated toric design. *J Cataract Refract Surg*. 2010; 36: 1523-1528.
- Sagiv O, Sachs D. Rotation stability of a toric intraocular lens with a second capsular tension ring. *J Cataract Refract Surg*. 2015; 41: 1098-1099.
- Safran S. Use of a capsular tension ring to prevent early postoperative rotation of a toric intraocular lens in high axial myopia. *J Cataract Refract Surg*. 2015; 3: 41-43.
- Nava A, Suarez R. One-year follow-up of toric intraocular lens implantation in forme fruste keratoconus. *J Cataract Refract Surg*. 2009; 35: 2024-2027.
- Patel CK, Ormonde S, Rosen PH, Bron AJ. Postoperative intraocular lens rotation; a randomized comparison of plate and loop haptic implants. *Ophthalmology*. 1999; 106: 2190-2195.
- Lim SJ, Kang SJ, Kim HB, Apple DJ. Ideal size of an intraocular lens for capsular bag fixation. *J Cataract Refract Surg*. 1998; 24: 397-402.
- Tehrani M, Dick HB, Krummenauer F, Pfirrmann G, Boyle T, Stoffelns B. Capsule measuring ring to predict capsular bag diameter and follow its course after foldable intraocular lens implantation. *J Cataract Refract Surg*. 2003; 29: 2127-2134.
- Lee JY, Kang KM, Shin JP, Kim IT, Kim SY, Park DH. Two-year results of AcrySof toric intraocular lens implantation in patients with combined microincision vitrectomy surgery and phacoemulsification. *Br J Ophthalmol*. 2013; 97: 444-449.
- Packer M, Rajan M, Ligabue E, Heiner P. Clinical properties of a novel, glistening-free, single-piece, hydrophobic acrylic IOL. *Clinical Ophthalmology*. 2014; 8: 421-427.