



Spontaneous Ureteric Rupture after Forceps Delivery

Magdy Moustafa*

Department of Obstetrics and Gynecology, Frimley Park Hospital, UK

Clinical Image

A 33 years old lady was admitted to the central delivery suit for induction of labour at 40 weeks+3 days having had pre labour spontaneous rupture of the membranes for more than 24 hours. She had an easy mid cavity forceps delivery in theatre under epidural with 2 pulls and small episiotomy. A temperature of 39.3°C developed during labour and antibiotics was started. Full blood count and C reactive protein were within normal values. She was discharged a day after delivery in a good condition.

She was readmitted after 24 hours with right iliac fossa pain. Appendicitis was excluded by the surgical team with the advice to continue antibiotics and analgesia. An abdominal and pelvic ultrasound was suggestive of the presence of right broad ligament haematoma of 8 cm x 6 cm. She was treated conservatively for 3 days with no obvious improvement with right renal angle tenderness.

In view of deterioration and spikes of temperature, the decision was made for CT guided drainage of the collected fluid which was sent for culture and sensitivity. The laboratory suggested that the aspirated fluid is urine. CT abdomen and pelvis with contrast revealed retroperitoneal urinoma secondary to right ureteric damage 4 cm below the pelviureteric junction. A RJJ stent was performed during cystoscopy.

Two month later the patient had cystoscopy and removal of the ureteric stent. An intravenous urography 2 weeks later confirmed an intact ureter.

Non traumatic or spontaneous ureteral rupture in pregnancy and labour is a rare occurrence and has been previously described in the literature and is usually seen at the fornix and upper ureter [1]. The pathogenic pathway underlying non traumatic disruption of the urinary collecting system is an increased intraluminal pressure [2].

In pregnancy, urinary ductal system dilatation or hydronephrosis is common occurrence and seen approximately in 80% of cases, mostly in the right side [3]. However in our patient, she has not any renal scan all through pregnancy and it is difficult to know that there was an element of hydronephrosis during pregnancy.

The likelihood of an avulsive force injuring the ureter is unlikely as it is expected to be the lower part of the ureter and associated with extended vaginal tear reaching the fornix which is not the case in our patient. We hypothesize that the increased intraluminal pressure resulting from physiologic

OPEN ACCESS

*Correspondence:

Magdy Moustafa, Department of Obstetrics and Gynecology, Frimley Park Hospital, Portsmouth Road, Frimley Camberley Surrey, GU16 6HD, UK, Tel: 07894913997; E-mail: magdy_moustafa@live.co.uk

Received Date: 23 Aug 2017

Accepted Date: 31 Aug 2017

Published Date: 04 Sep 2017

Citation:

Moustafa M. Spontaneous Ureteric Rupture after Forceps Delivery. *Ann Clin Case Rep.* 2017; 2: 1430.

ISSN: 2474-1655

Copyright © 2017 Magdy Moustafa.

This is an open access article distributed under the Creative Commons Attribution License, which permits unrestricted use, distribution, and reproduction in any medium, provided the original work is properly cited.

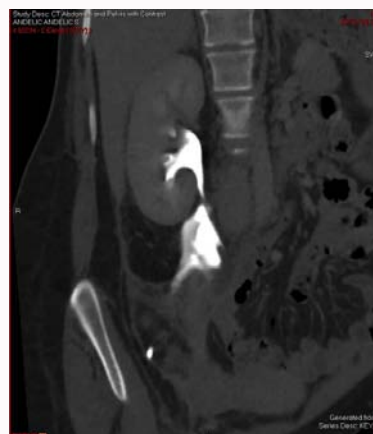


Figure 1: Coronal reconstruction of CT urogram showing extravasation of contrast from the proximal right ureter.

hydronephrosis of pregnancy in addition to rapid changes in intra-abdominal pressure while pushing might have resulted in the ureteral rupture.

The contrast enhanced CT scan is the preferred imaging study for renal trauma, to demonstrate the relationship between the urinoma and the urogenital tract and the fascial planes [4].

If urinoma is left untreated can lead to serious complications like perinephric abscess, urinary granuloma, retroperitoneal fibrosis, paralytic ileus, systemic sepsis, electrolyte imbalance and ureteric stenosis [5].

Rupture of the collecting system is best managed with drainage either by percutaneous nephrostomy or ureteric stenting, as in our case. The symptoms will usually resolve within days and the system will heal uneventfully.

Acknowledgement

The author is very grateful to DR/Germey Taylor Consultant Radiologist/Frimley Park Hospital for his help in preparing this article.

References

1. Pampana E, Altobelli S, Morini M, Ricci A, D'Onofrio S, Simonetti G. Spontaneous ureteral rupture diagnosis and treatment. *Case Rep Radiol.* 2013; 851859.
2. Narasimhulu DM, Egbert NM, Matthew S. Intrapartum spontaneous ureteral rupture. *Obstetrics Gynaecology.* 2015; 126: 610-612.
3. Dhabuwala CB, Riehle RA. Spontaneous rupture of hydronephrotic kidney during pregnancy. *Urology.* 1984; 24: 591-594.
4. Federle MP, Brown TR, Mc Aninch JW. Penetrating renal trauma: CT evaluation. *Journal of Computer Assisted Tomography.* 1987; 11: 1026-1030.
5. Kumar A, Suman SK, Khan I, Pridarshi S. Spontaneous perinephric urinoma in a postpartum woman: case report and review. *Int J Sci Stud.* 2014; 2: 154-156.