



Pregnancy in Patients with Established Liver Cirrhosis – An Uncommon but High-Risk Situation

Marcus Robertson^{1,2*}, Andrew Bathgate¹ and Peter Hayes¹

¹Department of Hepatology, Royal Infirmary of Edinburgh, United Kingdom

²Department of Gastroenterology, Monash Health, Melbourne, Australia

Abstract

Pregnancy is uncommon in females with liver cirrhosis but represents a complicated and high-risk clinical situation. Cirrhosis and portal hypertension may significantly worsen during pregnancy placing both the mother and foetus at risk of serious adverse events. In women with pre-existing portal hypertension, 30% - 64% will suffer from liver-related complications during or after pregnancy, most commonly manifesting as either variceal haemorrhage or hepatic decompensation, with maternal mortality rates of 1.8% - 7.8%. The MELD score is the only risk stratification tool validated to accurately predict liver-related complications during pregnancy, with a pre-conception MELD score ≥ 10 indicating a very high-risk of serious liver-related complications. Management necessitates a multidisciplinary approach including a maternal-foetal medicine specialist, hepatologist, neonatologist and anaesthetist. All patients require endoscopy (either before pregnancy or in the second trimester) to assess for the development of varices.

Keywords: Cirrhosis; Portal hypertension; Pregnancy; Varices; Variceal bleeding

Introduction

Pregnancy is an uncommon event in females with liver cirrhosis but represents a complicated and high-risk clinical situation that places both the mother and foetus at risk of serious adverse events. Here we present a case recently managed in our Hepatology unit followed by a review of the literature.

Case Presentation

A 22-year-old primiparous female was admitted to the hepatology ward at 20 weeks gestation for management of first-presentation decompensated chronic liver disease. This occurred on the background of long-standing liver cirrhosis with portal hypertension (PH) secondary to inherited alpha1-antitrypsin ($\alpha 1AT$) deficiency (PiZZ phenotype).

The patient had a past medical history significant for exercise-induced asthma, gastro-oesophageal reflux disease (GORD), childhood obesity, cholelithiasis with previous cholecystitis (managed conservatively) and visceral hypersensitivity manifesting as recurrent episodes of right upper quadrant pain. Medications included omeprazole and senna and the patient had documented allergies to penicillin and non-steroidal anti-inflammatory drugs (NSAIDs). The patient lived with her partner and was not currently working. She was a life-long non-smoker and consumed no alcohol. The patient had a strong family history of $\alpha 1AT$ deficiency with her mother dying of emphysema age 50 and a paternal uncle with $\alpha 1AT$ deficiency and no known complications.

The patient was diagnosed with $\alpha 1AT$ deficiency in 2007 by a paediatric Gastroenterologist and had compensated cirrhosis with portal hypertension at the time of diagnosis. A gastroscopy in 2007 revealed small (Grade 1) oesophageal varices which required no treatment. The patient was transitioned to adult care in 2009 and subsequently commenced on a variceal banding programme for primary prophylaxis in 2010. She was noted to have a long history of stable cirrhosis with no previous decompensations.

In 2015 the patient noted her menses to be three weeks late and was subsequently found to be unexpectedly pregnant. She was referred to the high-risk pregnancy clinic at our centre at 16 weeks gestation and a shared-care arrangement with the patient's Hepatologist was organised. The patient and her partner were extensively counselled about the risks of pregnancy - which included liver decompensation, a high-risk of life-threatening maternal haemorrhage and pre-term delivery

OPEN ACCESS

*Correspondence:

Marcus Robertson, c/ Monash Health
Gastroenterology and Hepatology Unit
246 Clayton Road, Clayton, Victoria,
Australia 3068, Tel: 00 61 3 9594 6666;
Fax: 00 61 3 9554 8554;
E-mail: Marcus.Robertson@
monashhealth.org

Received Date: 03 Aug 2017

Accepted Date: 28 Aug 2017

Published Date: 30 Aug 2017

Citation:

Robertson M, Bathgate A, Hayes P.
Pregnancy in Patients with Established
Liver Cirrhosis – An Uncommon but
High-Risk Situation. *Ann Clin Case
Rep.* 2017; 2: 1426.

ISSN: 2474-1655

Copyright © 2017 Marcus Robertson.

This is an open access article
distributed under the Creative
Commons Attribution License, which
permits unrestricted use, distribution,
and reproduction in any medium,
provided the original work is properly
cited.

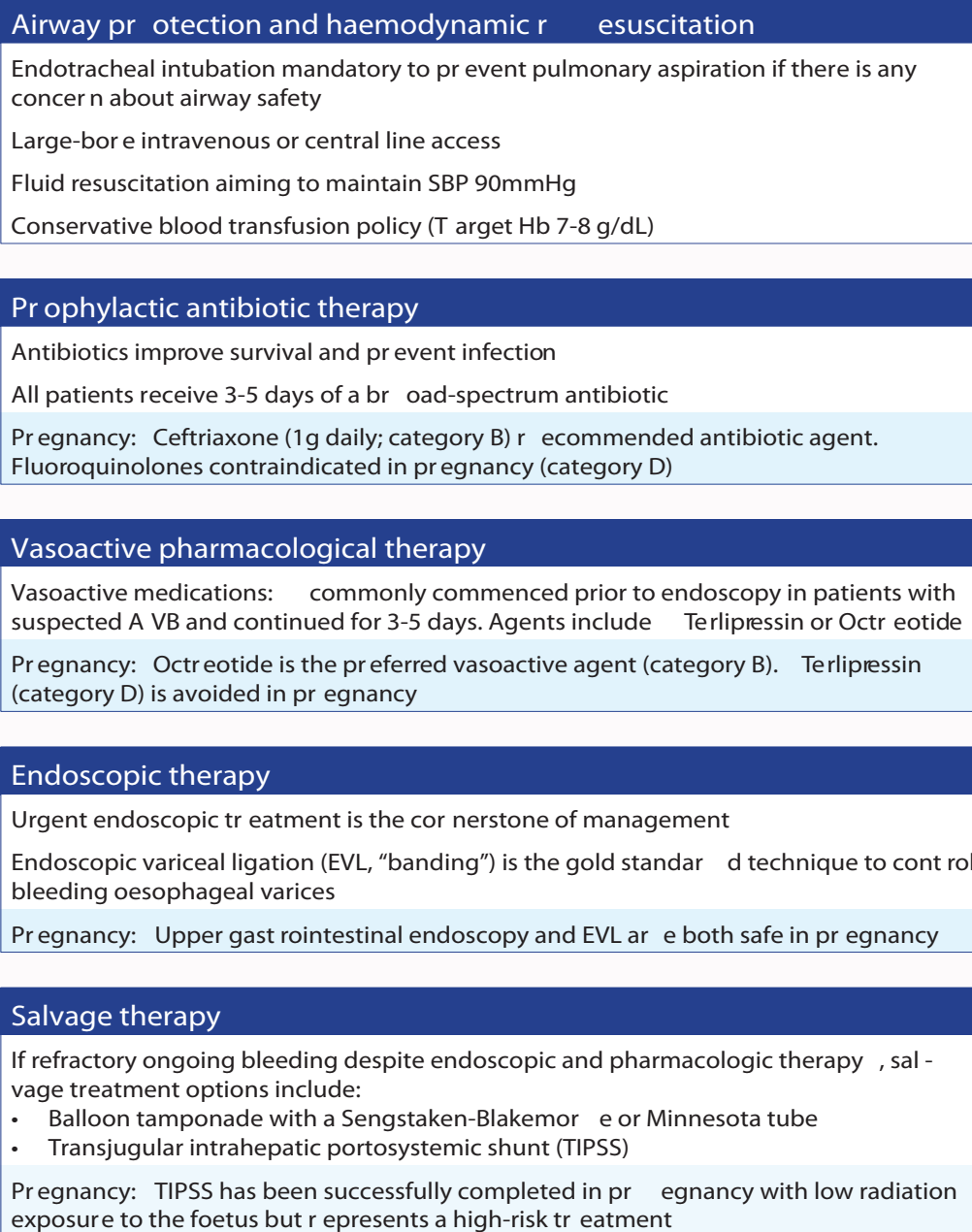


Figure 1: Management algorithm for acute variceal bleeding with pregnancy-specific management options highlighted. SBP: systolic blood pressure; Hb: Haemoglobin

– however they remained steadfastly of the opinion to continue with the pregnancy. A second trimester gastroscopy to assess varices was planned and the patient was informed it was likely non-selective β -blockers would be commenced to decrease the risk of variceal haemorrhage. The patient had stable liver function tests (LFTs) and a normal prothrombin time (PT) of 11 with a baseline Model for End-stage Liver Disease (MELD) score of 9, but was noted to have a falling albumin of 22 g/L and chronic thrombocytopenia (platelets 76×10^9 cells/L) secondary to portal-hypertension-related hypersplenism.

At 20 weeks gestation the patient was admitted with acute right upper quadrant pain and high-grade fevers secondary to *Streptococcus viridans* bacteraemia from a skin infection. This infection precipitated the patient's first episode of decompensated

cirrhosis with development of jaundice and moderate ascites. The ascites was managed with introduction of a low-salt diet and diuretics (spironolactone and furosemide). Intravenous clindamycin was administered with resolution of symptoms and gradual liver re-compensation (normalisation of bilirubin and resolution of ascites). The possibility of termination of pregnancy was again discussed during this admission however the patient was adamant she wished to continue with the pregnancy.

At 23 weeks gestation the patient was noted to have deteriorating LFTs with impaired synthetic function (albumin 21, PT 16) and stable thrombocytopenia. At 24 weeks gestation the patient was admitted to the obstetric unit with worsening LFTs, proteinuria and hypertension and subsequently diagnosed with pre-eclampsia

and decompensated cirrhosis. The patient rapidly deteriorated and emergency caesarean section with delivery of a live male foetus was performed 24 hours later, at which time large-volume ascites was noted. The patient was admitted to the intensive care unit (ICU) post-operatively for management of multiple complications including acute kidney injury (peak creatinine 280 $\mu\text{mol/L}$) with oligo-anuria and liver decompensation with development of ascites and jaundice.

Unfortunately, the patient's son died 48 hours after delivery. Following discharge from ICU, the patient required prolonged hospitalisation during which time she was accepted for liver transplantation assessment. The patient has now received a liver transplant and remains well.

Discussion

Historically, women with liver cirrhosis were considered infertile with case reports detailing occasional successful pregnancies. Two main factors account for pregnancy being an unusual event in patients with cirrhosis. Firstly, female patients with cirrhosis have reduced fertility as the metabolic and hormonal derangements associated with the condition lead to anovulation and amenorrhoea [1,2]. In addition, it typically takes many years to progress to advanced liver disease and cirrhosis and thus, the condition is not commonly encountered in women of child-bearing age [3]. It is clear, however, that pregnancies in women with cirrhosis are increasing. A population-based study performed in the USA by Shaheen and Myers demonstrated an increase in mean nationwide deliveries from 68 annually between 1993 and 1999 to 106 annually between 2000 and 2005 [4]. As treatment of chronic liver disease continues to improve, it is likely that conception rates and pregnancies in cirrhotic patients will continue to increase.

Unplanned pregnancy in patients with liver cirrhosis is a high-risk and complicated clinical scenario with risks to both mother and foetus. Unplanned and/or unwanted pregnancies represented 38% of the cohort in one study [5] and expose the mother and foetus to significant risks. In addition, the safety of planned termination of pregnancy is not known in cirrhotic patients with evidence limited to isolated case reports. Thus, although it remains an uncommon clinical scenario, contraceptive counselling should be provided to all women of child-bearing age with liver cirrhosis.

The haemodynamic and physiological changes that occur throughout pregnancy can exacerbate pre-existing PH in women with cirrhosis. Increases in maternal cardiac output and blood volume, along with a decrease in systemic vascular resistance result in a hyperdynamic circulatory state, which increase pressures in the portal venous system [6]. In women with pre-existing cirrhotic or non-cirrhotic PH 30% - 64% will suffer from liver-related complications during or after pregnancy, most commonly manifesting as either variceal haemorrhage or hepatic decompensation [4,6-8]. The largest case series have shown maternal mortality rates of 1.8% to 7.8% [4,8]

Oesophageal varices

Acute variceal bleeding (AVB) has been reported in 18-32% of pregnant women with cirrhosis and in up to 50% of those with known PH [9,10]. In women with known pre-existing varices, up to 78% will experience gastrointestinal bleeding during pregnancy with a quoted mortality rate of 18%-50% [2]. These statistics paint a grim picture but it is important to remember they are based on old studies. Advancements in the management of AVB have resulted

in significant improvements in mortality in non-pregnant patients [11-14] and thus outcomes in pregnant patients are likely to have also improved. Variceal bleeding most commonly occurs during the second and third trimesters when maternal blood volume is maximally expanded [3].

All patients require a screening endoscopy to assess for the development of varices which typically occurs either before pregnancy and/or early in the second trimester [15]. Westbrook et al. demonstrated 50% of screened patients to have varices at this time, and found a pre-pregnancy platelet count less than 110×10^9 cells/L to accurately predict the presence of varices in the second trimester with a sensitivity of 78% and specificity of 89% [5]. Patients at risk of variceal bleeding should receive primary or secondary prophylaxis with either a non-selective beta-blocker or oesophageal variceal ligation. Beta blockers are generally considered safe in pregnancy; possible risks include foetal bradycardia, growth retardation and neonatal hypoglycaemia [6]. Management of AVB is similar to non-pregnant patients with the exception that octreotide (Category B) is preferred to terlipressin (category D) as a vasoactive agent (Figure 1).

Hepatic decompensation

Up to 24% of pregnant patients with cirrhosis may experience liver dysfunction and hepatic decompensation, which can manifest as jaundice, ascites and/or hepatic encephalopathy [3,16]. Hepatic decompensation may occur at any stage in pregnancy and risk factors include variceal bleeding, infection and drugs.

Foetal risks and outcomes

Advanced liver disease is associated with poorer pregnancy outcomes. Women with liver cirrhosis have a higher incidence of spontaneous abortion and stillbirth than that of the general population [3,5], with one retrospective review documenting a live birth rate of 58% [5]. In pregnancies that do result in live births, studies show foetal complication rates around 49%, with significantly increased risks of prematurity (39% vs. 10% in the general population), intrauterine growth restriction (5.3% vs. 2.1%) and perinatal mortality (5.2% vs. 2.1%) [4]. Foetal mortality was high in the setting of maternal hepatic decompensation (12%) and variceal haemorrhage (11%) [4].

Risk evaluation and counselling in pregnant women with liver cirrhosis

The complications and consequences of pregnancy in women with cirrhosis can be variable and unpredictable. Undoubtedly women with advanced cirrhosis and/or PH are at the greatest risk of developing significant complications. Westbrook et al. [5] determined the MELD score was the only risk stratification tool that accurately predicted complications, with higher MELD scores at the time of conception correlating with an increased risk of liver-related complications during pregnancy. Patients with a MELD score of 6 had minimal risk of significant complications. A MELD score of ≥ 10 prior to conception had an 83% sensitivity and specificity for predicting a serious liver-related complication during pregnancy or following delivery [5].

Recommendations for management

Evidence to guide management of pregnancy in patients with liver cirrhosis is sparse and largely based on case-reports and small case series. It is clear however that management of these patients necessitates a multidisciplinary approach including high-risk obstetric and/or maternal-foetal medicine specialist, hepatologist, neonatologist and anaesthetist.

Pre-pregnancy management including contraceptive and pre-conception counselling

In women wishing to become pregnant, extensive pre-conception counselling with both an Obstetrician and Hepatologist is recommended. Patients should be educated about the risks of pregnancy, which will depend greatly on the aetiology and severity of the patient's underlying liver disease. All patients should be risk stratified using the MELD score and patients with a MELD score ≥ 10 counselled that they are at particularly high risk of serious liver-related complications. Pregnancy should be planned when a patient's underlying liver disease is stable, with regular hepatology and obstetric follow-up and close monitoring throughout the entire ante-partum period. In high-risk patients, alternatives such as liver transplantation or TIPSS could be considered prior to consideration of pregnancy.

Antenatal management

Antenatal management requires careful monitoring of the mother and foetus by a high-risk obstetric/maternal-foetal-medicine unit and a specialist Hepatologist. Liver function (including liver synthetic function with serum albumin and INR/PT) should be checked at least every four weeks and patients should be examined for signs of decompensation such as ascites, jaundice or encephalopathy. Full blood count should also be closely monitored as patients with portal hypertension may develop worsening thrombocytopaenia or anaemia; anaemia may require treatment to avoid maternal (cardiac compromise) and foetal (pre-term labour, low birth weight) complications [6]. Foetal growth also requires careful monitoring. Pregnancy should proceed to term if the patient and foetus remain stable. Early termination of pregnancy may be warranted in the setting of severe liver decompensation or progressive liver failure.

Peripartum management

There are no recommendations as to the preferred mode of delivery in patients with cirrhosis and PH. Vaginal delivery appears to be safe and caesarean section is usually reserved for obstetric indications. In patients with advanced cirrhosis, intra-abdominal surgery confers a significant risk of liver decompensation and bleeding risks are high due to coagulopathy, thrombocytopaenia and the possibility of ectopic varices. The second stage of labour may be shortened prophylactically to avoid prolonged straining by the mother, which may increase the risk of variceal haemorrhage. Variceal bleeding during labour is well described, secondary to increased intra-abdominal pressure during labour leading to elevated portal pressures [8,15]. One suggested method to lower risks during vaginal delivery is to place an epidural early in labour, allow the infant to descend with uterine contractions alone, followed by assisted delivery with forceps or vacuum extraction. The third stage of labour should be managed actively; the risk of post-partum haemorrhage should be anticipated and vigilantly managed.

Conclusions

Pregnancy in females with liver cirrhosis represents a

complicated and high-risk clinical situation that should be managed by a multidisciplinary team including a high-risk obstetric unit and a specialist Hepatologist. If possible, pregnancy should be a planned event that occurs in the setting of stable liver disease and treated varices; this case highlights the dangers of unplanned pregnancies in patients with cirrhosis.

References

- Lloyd CW, Williams RH. Endocrine changes associated with Laennec's cirrhosis of the liver. *Am J Med.* 1948; 4: 315-330.
- Russell MA, Craigo SD. Cirrhosis and portal hypertension in pregnancy. *Semin Perinatol.* 1998; 22: 156-165.
- Tan J, Surti B, Saab S. Pregnancy and cirrhosis. *Liver Transpl.* 2008; 14: 1081-1091.
- Shaheen AA, Myers RP. The outcomes of pregnancy in patients with cirrhosis: a population-based study. *Liver Int.* 2010; 30: 275-283.
- Westbrook RH, Yeoman AD, O'Grady JG, Harrison PM, Devlin J, Heneghan MA. Model for end-stage liver disease score predicts outcome in cirrhotic patients during pregnancy. *Clin Gastroenterol Hepatol.* 2011; 9: 694-699.
- Aggarwal N, Negi N, Aggarwal A, Bodh V, Dhiman RK. Pregnancy with portal hypertension. *J Clin Exp Hepatol.* 2014; 4: 163-171.
- Sandhu BS, Sanyal AJ. Pregnancy and liver disease. *Gastroenterol Clin North Am.* 2003; 32: 407-436.
- Rasheed SM, Abdel Monem AM, Abd Ellah AH, Abdel Fattah MS. Prognosis and determinants of pregnancy outcome among patients with post-hepatitis liver cirrhosis. *Int J Gynaecol Obstet.* 2013; 121: 247-251.
- Britton RC. Pregnancy and esophageal varices. *Am J Surg.* 1982; 143: 421-425.
- Pajor A, Lehoczy D. Pregnancy in liver cirrhosis. Assessment of maternal and fetal risks in eleven patients and review of the management. *Gynecol Obstet Invest.* 1994; 38: 45-50.
- Chalasan N, Kahi C, Francois F, et al. Improved patient survival after acute variceal bleeding: a multicenter, cohort study. *Am J Gastroenterol.* 2003; 98: 653-659.
- Carbonell N, Pauwels A, Serfaty L, Fourdan O, Lévy VG, Poupon R. Improved survival after variceal bleeding in patients with cirrhosis over the past two decades. *Hepatology.* 2004; 40: 652-659.
- El-Serag HB, Everhart JE. Improved survival after variceal hemorrhage over an 11-year period in the Department of Veterans Affairs. *Am J Gastroenterol.* 2000; 95: 3566-3573.
- Vuachet D, Cervoni J-P, Vuitton L, Weil D, Dritsas S, Dussaucy A. Improved survival of cirrhotic patients with variceal bleeding over the decade 2000-2010. *Clin Res Hepatol Gastroenterol.* 2015; 39: 59-67.
- Esposti SD. Pregnancy in patients with advanced chronic liver disease. *Clin Liver Dis.* 2014; 4: 62-68.
- Benjaminov FS, Heathcote J. Liver disease in pregnancy. *Am J Gastroenterol.* 2004; 99: 2479-2488.